

# Post-Pleuropneumectomy Herniation of Liver Mimicking Major Pulmonary Embolism



Hanno Huwer, Johannes Winning\*, Helmut Isringhaus,  
Gerhard Kalweit

Department of Cardiothoracic Surgery, Völklingen Heart Centre, and \*Clinic for Anesthesiology and Intensive Care Medicine, Friedrich-Schiller University of Jena

## Introduction

Complete resection, neither decortication or pleuropneumectomy, in a multimodality treatment setting, seems to be promising in selected patients with malignant pleural mesothelioma. The mortality of pleuropneumectomy has decreased in recent years from 30 % to < 5 %. The majority of patients who die after major lung resections suffer from complications of the remaining lung or problems related to the operation. Pulmonary embolism is the second most frequent cause of death in the early postoperative course. An unusual complication after right-sided pneumonectomy and hemidiaphragm resection, which presented with clinical symptoms of major pulmonary embolism, is described.

## Clinical Summary

A 58-year-old man was admitted with a 4-month history of dyspnea and right sided chest pain. He had been exposed to asbestos for years. Chest radiography showed a pleural effusion and computed tomography revealed pleural thickening, effusion, and reduced volume of the right hemithorax. Thoracocentesis resulted negative fluid tests. Thoracoscopically obtained biopsies yielded a diagnosis of an epithelioid mesothelioma. The preoperative tumor stage was assessed as T3N0.

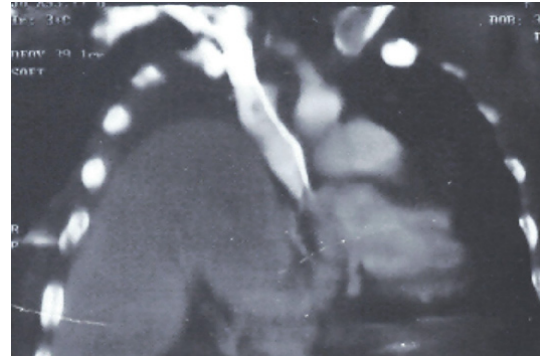
A right pleuropneumectomy was performed. Firstly the extrapleural dissection was conducted. Subsequently the pericardium was opened to rule out the presence of intrapericardial tumor. Thereafter the right-sided pericardium and the whole diaphragm were resected and a intrapericardial pneumonectomy was performed. The pericardium was reconstructed using a prosthetic patch and similarly the diaphragm was replaced by patch sewn circumferentially to the remnants of the crura, the hiatal musculature, the chest wall, and the pericardial patch. Histology confirmed the diagnosis epithelioid mesothelioma. Due to a hilar lymph node infiltration, the tumor stage was determined as T3N1. Postoperatively, the patient was transferred to the intensive care unit and was extubated the next morning. The chest drain was removed on the second postoperative day. The early post-operative course was uneventful; he was transferred to the ward, and mobilized. Low-molecular-weight heparin was used for prophylaxis of venous thrombosis.

On the 9th postoperative day, he developed severe acute dyspnea after a forced Valsalva maneuver for bowel movement. He was dyspneic and restless and his skin was cold, clammy, and pale. Tachycardia of > 140 beats per minute and hypotension with a systolic blood pressure of 70 mm Hg were noted. Due to ongoing deterioration and under the assumption of fulminant pulmonary embolism, the patient was intubated and mechanically ventilated. An electrocardiogram showed sinus tachycardia and nonsignificant ST-elevations in all leads. Blood gas analysis during mechanical ventilation with a fraction of inspired oxygen of 1.0 revealed pO<sub>2</sub> of 325 mmHg, pCO<sub>2</sub> of 45 mmHg, and SaO<sub>2</sub> of 100%. On transthoracic echo-cardiography, no clear images could be obtained from the precordial or subcostal positions. A crystalloid solution and bolus thrombolytic therapy with recombinant tissue plasminogen activator (rt-PA) were administered without further diagnostic evaluation.

During continuous infusion of a crystalloid solution and norepinephrine (0.3 µg/kg body weight x min), the circulation stabilized. Left-sided pneumothorax was ruled out by chest radiography. Spiral computed tomography demonstrated no filling defects in the pulmonary arteries, but the liver was displaced into the right hemithorax (Fig. 1). A repeat thoracotomy revealed that the prosthetic patch replacing the diaphragm had broken away, and the liver had completely herniated into the hemithorax. After repositioning of the liver into the abdomen, the circulation normalized quickly and inotropic substances could be withdrawn. The diaphragm was again reconstructed using a patch. The further postoperative course was uneventful.

## Discussion

Patients undergoing pneumonectomy are at high risk of a fatal outcome due to thromboembolic events. Our patient presented with clinical symptoms of acute major pulmonary embolism: sudden onset of dyspnea and cardiovascular collapse. From reported series, it is evident that a large embolus with cardiopulmonary dysfunction leading to shock is associated with a mortality rate of approximately 30 %. Therefore, the



Herniation of the liver into the right hemithorax

tempo of evaluation must be rapid. A myriad of EKG manifestations have been reported during major pulmonary embolism. The most common EKG findings are abnormalities in the ST segment and T waves and changes due to acute cor pulmonale, but a normal EKG is reported in 15% - 30%. Our patient presented with unspecific ST-segment elevation that might be explained by resection of the right-sided pericardium. Echocardiography is useful in the recognition and differentiation of major pulmonary embolism. A normal echocardiogram without signs of right ventricular pressure overload effectively eliminates pulmonary embolism as the cause of a shock state. In this case, no proper images could be obtained by transthoracic echocardiography. This might have been due to the supine position of this hemodynamically unstable patient, positive-pressure ventilation after right-sided pneumonectomy, or intrathoracic and intra-abdominal anatomical irregularities caused by herniation of the liver. To avoid further delay in therapy, transesophageal echocardiography was not performed. The parameters of the blood gas analyses during mechanical ventilation were within the normal range although the patient had suffered from dyspnea prior to intubation. This apparent discrepancy may be explained by the acute deterioration of cardiac output which leads to a reduction in O<sub>2</sub> delivery at the cellular level. The treatment of choice in hemodynamically unstable patients with pulmonary embolism is thrombolytic therapy, whenever feasible. As we suspected a major pulmonary embolism, thrombolytic therapy without further diagnostic procedures was instituted in this case.

Herniation of the liver is mostly a topic of the trauma literature. Rupture of the right diaphragm rarely causes early symptoms in severely injured patients on mechanical ventilation, which can impede dislocation of the liver into the hemithorax. Even after right sided pneumonectomy and diaphragm resection, the risk of hepatothorax is regarded as low, leading to the opinion that reconstruction of the diaphragm on the right side may not be necessary.

In our patient, a forced Valsalva maneuver caused prosthetic patch rupture and herniation of the liver into the empty hemithorax, with concomitant deviation of the inferior vena cava (Fig. 1). As a consequence of the serial alignment of the right heart pump and the left heart pump, left heart output cannot exceed venous return or right heart output. Approximately 65-70 % of the total venous return to the right heart originates from the inferior caval vein, and approximately 50 % of the inferior caval vein volume originates from the liver. Acute inferior caval vein obstruction reduces venous return, and acute pulmonary embolism reduces right heart output; thus, both lead to low left heart output which is responsible for the subsequent clinical signs and symptoms.

In animal experiments, acute suprarenal caval occlusion alone induces marked hemodynamic effects, with an immediate 60 % reduction in cardiac output. These hemodynamic consequences occur within 5 minutes after ligation, and moderate spontaneously over the next hour. If suprahepatic inferior caval vein occlusion occurs acutely, the total venous return is significantly reduced. The clinical appearance of shock and dyspnea is explained by the impaired venous return. The partial response to medical treatment with crystalloids and catecholamines supports this assertion.